

CLINICAL PRACTICE GUIDELINES

EANO–ESMO Clinical Practice Guidelines for diagnosis, treatment and follow-up of patients with leptomeningeal metastasis from solid tumours[†]

E. Le Rhun^{1,2,3}, M. Weller⁴, D. Brandsma⁵, M. Van den Bent⁶, E. de Azambuja⁷, R. Henriksson^{8,9}, T. Boulanger¹⁰, S. Peters¹¹, C. Watts¹², W. Wick^{13,14}, P. Wesseling^{15,16}, R. Rudà¹⁷ & M. Preusser¹⁸, on behalf of the EANO Executive Board and ESMO Guidelines Committee*

¹Neuro-Oncology, Department of Neurosurgery, Lille University Hospital, Lille; ²Neurology, Medical Oncology Department, Oscar Lambret Center, Lille; ³Lille University, Inserm U-1192, Villeneuve d'Ascq, France; ⁴Department of Neurology and Brain Tumour Center, University Hospital, Zurich, Switzerland; ⁵Department of Neuro-Oncology, Netherlands Cancer Institute, Amsterdam; ⁶The Brain Tumour Center at the Erasmus MC Cancer Institute, Rotterdam, The Netherlands; ⁷Medical Oncology Department, Institut Jules Bordet and L'Université Libre de Bruxelles (U.L.B.), Brussels, Belgium; ⁸Regional Cancer Center, Stockholm; ⁹Department of Radiation Sciences and Oncology, University, Umea, Sweden; ¹⁰Neuroradiology, Imaging Department, Oscar Lambret Center, Lille, France; ¹¹Department of Oncology, University Hospital, Lausanne, Switzerland; ¹²Division of Neurosurgery, Department of Clinical Neurosciences, University of Cambridge, Cambridge, UK; ¹³Neurology Clinic, Heidelberg University Hospital, Heidelberg; ¹⁴Clinical Cooperation Unit Neuro-Oncology, German Consortium for Translational Cancer Research (DKTK), German Cancer Research Centre (DKFZ), Heidelberg, Germany; ¹⁵Department of Pathology, VU University Medical Centre and Brain Tumour Center, Amsterdam; ¹⁶Department of Pathology, Princess Máxima Center for Paediatric Oncology and University Medical Centre Utrecht, Utrecht, The Netherlands; ¹⁷Department of Neuro-Oncology, City of Health and Science Hospital, University of Turin, Turin, Italy; ¹⁸Clinical Division of Oncology, Department of Medicine 1, CNS Unit Comprehensive Cancer Centre (CCC-CNS), Medical University, Vienna, Austria

*Correspondence to: ESMO Guidelines Committee, ESMO Head Office, Via L. Taddei 4, CH-6962 Viganella-Lugano, Switzerland. E-mail: clinicalguidelines@esmo.org or EANO Office, c/o WMA GmbH | Alser Strasse 4, 1090 Vienna, Austria; E-mail: office@eano.eu

[†]These Guidelines were developed by the European Society for Medical Oncology (ESMO) and the European Association of Neuro-Oncology (EANO).



EANO
EUROPEAN ASSOCIATION
OF NEURO-ONCOLOGY
www.eano.eu



GOOD SCIENCE
BETTER MEDICINE
BEST PRACTICE

The two societies nominated authors to write the guidelines as well as reviewers to comment on them. These guidelines were approved by the EANO Executive Board and the ESMO Guidelines Committee in May 2017.

Introduction

These EANO–ESMO joint recommendations for the diagnosis and treatment of leptomeningeal metastasis (LM) from solid cancers represent the first European guideline initiative on this topic. LM is defined as the spread of tumour cells within the leptomeninges and the subarachnoid space, is synonymous with ‘neoplastic meningitis’ and can be further denoted by primary tumour as leptomeningeal carcinomatosis, gliomatosis or lymphomatosis. The recommendations address LM from solid tumours, but neither LM from primary brain tumours nor LM from lymphoma or leukaemia. They cover prevention, diagnosis, therapy and follow-up, but not differential diagnosis, adverse effects of therapeutic measures or supportive or palliative care. We propose diagnostic criteria as well as a neuroimaging- and cytopathology-based classification of LM syndromes to derive pragmatic treatment algorithms. We also assign levels of certainty to the diagnosis of

LM to provide guidance when to treat (as opposed to when to intensify diagnostic efforts) and on which patients to include in clinical trials. Given the low level of evidence, the recommendations are based more on expert opinion and consensus than on evidence from informative clinical trials. Still, the EANO–ESMO multidisciplinary recommendations shall serve as a valuable source of information for physicians, other health care providers, as well as informed patients and relatives.

Epidemiology

LM may be diagnosed in approximately 10% of patients with metastatic cancer in the course of disease [1]. The incidence is probably underestimated because of non-specific symptoms and signs, lack of sensitivity to diagnostic procedures and limited

therapeutic options. Breast cancer, lung cancer and melanoma represent the three most common causes of LM, but LM may be observed with all malignant tumours. LM occurs in the context of progressive systemic disease in approximately 70% of solid cancer patients with LM, in around 20% at the time of first progression after initial treatment, but in up to 10% already at the time of diagnosis. In recent large cohorts of LM patients, brain metastases were associated with LM in 33%–54% of breast cancer, 56%–82% of lung cancer and 87%–96% of melanoma patients [2–20].

Risk factors for the development of LM include opening of the ventricular system during brain metastasis surgery or resection of cerebellar metastases, especially when using a piecemeal resection [21–26]. In a large cohort of patients with brain metastasis, the incidence of LM was higher in patients treated with surgery followed by stereotactic radiosurgery than in patients treated with radiosurgery alone [27].

Patients with lobular subtype and triple-negative tumours have a relatively higher risk of LM than patients with other types of breast cancer [28]. In recent cohorts, primary breast tumours causing LM were ductal carcinoma in 51%–78%, lobular carcinoma in 26%–35%, human epidermal growth factor receptor-2 (HER2)-positive in 10%–29% (up to 47% in only one series) and triple negative in 22%–40.5% [2–7, 9–12, 28].

Lung tumours causing LM were adenocarcinomas in 84%–96% [13–16, 19]. Epidermal growth factor receptor (EGFR)-mutant lung cancer may have a central nervous system (CNS) tropism [29–31]. Metastatic CNS involvement has also been recognised as an emerging complication in patients with anaplastic lymphoma kinase (ALK)-positive non-small-cell lung cancer (NSCLC) [32, 33]. In a second-line trial for ALK-positive disease, approximately 35% of ALK-positive patients had brain metastasis at the time of study entry [34].

Only a few large cohorts of melanoma patients with LM have been reported and risk factors, including LM risk-associated molecular profiles (e.g. *BRAF* mutation status), have not been identified.

The role of cerebrospinal magnetic resonance imaging (MRI) in addition to standard extracerebral staging during the follow-up of patients at high risk of LM (e.g. with triple-negative or lobular breast cancer) has not been evaluated.

Recommendation:

- LM should be considered in particular in patients with breast or lung cancer or melanoma who present with neurological symptoms or signs [EANO: III, C; ESMO: III, B].

Prognosis

Median survival is poor and limited to 6–8 weeks without tumour-specific treatment whereas survival may be prolonged to a few months with LM-directed treatment, including targeted therapy and immunotherapy: 1.75–4.5 months in breast cancer, 3–6 months in lung cancer and 1.7–2.5 months in melanoma (cohorts of more than 30 patients published within the last 10 years) [2–7, 9–20, 28]. Published survival rates at 1 year were 16%–24% for breast cancer [5, 12], 19% for lung cancer [13, 18] and 7% for melanoma patients [19]. Performance status at diagnosis of LM is the most important prognostic factor, as shown by multivariate analysis. Other frequently reported prognostic factors include

primary tumour type, cerebrospinal fluid (CSF) protein levels, administration of combined modality treatment, systemic treatment or intra-CSF treatment, and initial clinical or CSF responses to treatment [2–5, 9–11, 35–39]. In contrast, an association of whole brain radiotherapy (WBRT) with overall survival (OS) has not been consistently reported [13–16, 28].

Pathogenesis

The invasion of the leptomeninges by tumour cells may occur by haematogenous spread through the arterial or venous circulation, or endoneural, perineural, perivascular or lymphatic spread, especially from breast and lung cancers. Furthermore, there may be a direct invasion from brain or spinal parenchymal metastases in contact with the CSF, the choroid plexus and from subependymal metastases [40–42]. Iatrogenic spread may occur after neurosurgical interventions, notably when lesioning the ventricles [22]. *De novo* tumours originating in the leptomeninges with melanoma histology are also observed, but represent a distinct disease entity [43]. Once seeded in the meninges, tumour cells may disseminate along the meningeal and ependymal surfaces or with the CSF flow, with a predilection of colonising regions of slow CSF flow and gravity-dependent locations, e.g. posterior fossa, basilar cisterns and lumbar cistern [40]. Molecular factors facilitating seeding of the leptomeninges by tumour cells have not been identified.

Clinical presentation

Symptoms and signs are related to the specific CNS areas involved by LM and thus are typically multifocal. The most frequent manifestations at presentation [2, 3, 5–7, 11, 13, 15, 18–20, 44] are as follows:

- headache;
- nausea and vomiting;
- mental changes;
- gait difficulties;
- cranial nerve palsies, e.g. with diplopia or visual disturbance (cranial nerve VI, III, IV, II) and hearing loss (cranial nerve VIII);
- radicular signs including weakness, voiding and cauda equina problems; and
- focal or irradiating (radicular) neck and back pain.

Some of these symptoms and signs are in part or largely related to increased intracranial pressure due to CSF circulation disturbances and can be rapidly alleviated by lowering intracranial pressure through CSF drainage. Patients may also present with subtle isolated symptoms and signs. Bladder, sexual and bowel dysfunction are possibly underreported and should be explored at presentation and during the course of the disease. To ensure appropriate clinical management strategies, symptoms or signs due to parenchymal metastases, extracranial disease, side-effects of treatments or non-cancer comorbidities should be distinguished from LM-related neurological symptoms and signs. A detailed neurological examination is required and a standard evaluation form should be used for the clinical evaluation of patients at diagnosis and during follow-up [1]. The Neurologic

Assessment in Neuro-Oncology (NANO) criteria used to assess neurological function in brain tumour patients [45] are unlikely to be useful in LM patients because they do not address the multi-level involvement of the CNS typically seen in LM.

Recommendations:

- Typical clinical signs of LM such as headache, nausea and vomiting, mental changes, gait difficulties, cranial nerve palsies with diplopia, visual disturbances, hearing loss, sensorimotor deficits of extremities and cauda equine syndrome, radicular, neck and back pain, notably in a patient with cancer, should alert clinicians to consider LM [EANO: IV, n/a; ESMO: V, n/a].
- A detailed neurological examination using a standard evaluation form, e.g. as proposed by the Leptomeningeal Assessment in Neuro-Oncology (LANO) group, should be carried out at diagnosis [EANO: IV, n/a; ESMO: V, n/a].

Diagnostic procedures

Neuroimaging

Cerebrospinal MRI without and with contrast enhancement using at least 1.5-T field strength is the ‘gold standard’ for the

comprehensive neuroradiological assessment of patients with suspected LM (Table 1) [46]. Characteristic MRI findings include sulcal enhancement or obliteration, linear ependymal enhancement, cranial nerve root enhancement and leptomeningeal enhancing nodules, notably of the cauda equina. Prospective systematic studies addressing sensitivity and specificity of MRI in distinguishing LM from other diseases with a similar MRI pattern have not been conducted. Sensitivity and specificity of cerebrospinal MRI remain difficult to appreciate due to a limited number of publications in patients with a suspicion of LM and improvement of technique over time, but have been estimated in the range of 66%–98% and 77%–97.5%, respectively [47–50]. In recently reported cohorts, 68%–97% of patients with a diagnosis of LM based on presence of tumour cells in the CSF or on typical clinical and MRI findings had radiological evidence of LM on cerebrospinal MRI, indicating that the diagnosis of LM is infrequently made in patients with a normal MRI [2–5, 7, 9–11, 14, 16–20, 39, 44].

The neuroradiological assessment of LM is challenging. Contrast enhancement can be complex in geometry and small in volume [1]. Several technical issues, such as slice positioning and thickness, time interval between contrast injection and image acquisition influence the sensitivity and specificity of neuroimaging. Contrast-enhanced T₁-weighted and fluid-attenuated inversion recovery (FLAIR) sequences are probably the most sensitive for the detection of LM [51, 52]. Gadolinium should be

Table 1. Evaluation of suspected LM

	Recommended protocols of evaluation	Results
Clinical evaluation	Standardised neurological evaluation [1]	Presence of typical clinical signs of LM ^a Any other neurological abnormality Normal neurological evaluation
Neuroimaging	Brain: axial T ₁ -weighted, axial FLAIR, axial diffusion, axial T ₂ -weighted post-gadolinium 3D T ₁ -weighted and post-gadolinium 3D FLAIR sequences.	Typical MRI findings of linear LM (type A) ^b Typical MRI findings of nodular leptomeningeal disease (type B)
	Spinal axis: post-gadolinium sagittal T ₁ -weighted sequences. Spine sagittal T ₁ -weighted sequences without contrast and sagittal fat suppression T ₂ -weighted sequences, combined with axial T ₁ -weighted images with contrast of regions of interest, may also be considered.	Both (type C) No neuroimaging evidence of LM, except possibly hydrocephalus (type D)
CSF cytology	Fresh CSF samples should be processed within 30 min after sampling when feasible; alternatively, fresh CSF samples can be fixed with ethanol/Carbowax (CSF/fixative ratio 1 : 1) CSF volume is ideally > 10 mL but at least 5 mL Routine staining for cytological analysis: Pap/Papanicolaou and (in freshly processed CSF samples) Giemsa Additional immunocytochemical staining (upon indication and availability of material) for epithelial and melanocytic markers; in case of haematological malignancy in the differential diagnosis, consider immunostainings for lymphoid cells and/or flow cytometry analysis of the CSF sample A second CSF sample should be analysed if the initial CSF sample is negative	Positive: presence of tumour cells Equivocal: suspicious or atypical cells Negative: absence of tumour cells

^aTypical clinical signs of LM include headache, nausea and vomiting, mental changes, gait difficulties, cranial nerve palsies with diplopia, visual disturbances, hearing loss, sensorimotor deficits of extremities and cauda equine syndrome, and radicular neck and back pain.

^bSee Table 2 and text.

CSF, cerebrospinal fluid; FLAIR, fluid-attenuated inversion recovery; LM, leptomeningeal metastasis; MRI, magnetic resonance imaging.

injected 10 min before data acquisition at a dose of 0.1 mmol/kg. The slice thickness should be ≤ 1 mm. As recommended by the LANO group, nodules should be defined as $\geq 5 \times 10$ mm in orthogonal diameters [1] and should be distinguished from linear contrast enhancement. As meningeal contrast enhancement may also be observed after lumbar puncture or ventricular shunt placement, cerebrospinal MRI should be obtained before such procedures whenever feasible. Communicating hydrocephalus is observed in 11%–17% of patients [9, 16]. Cerebrospinal MRI also detects brain metastasis, epidural spinal cord compression and intramedullary spinal cord metastases. Cranial computed tomography (CT) should be limited to patients with contraindications for MRI and mainly helps to identify nodular disease. 18F-fluorodeoxyglucose positron emission tomography-computed tomography (FDG-PET-CT) is rarely useful for the diagnosis of LM [53]. CSF flow studies using intra-CSF application of tracers, such as 111 Indium-diethylene triamine pentaacetic acid (DTPA) or 99m Technetium macro-aggregated albumin, have been recommended for patients considered candidates for intra-CSF pharmacotherapy, as obstruction to CSF flow may impede coverage of the target volume of drug distribution [1]. CSF flow abnormalities have been observed in 61%–70% of patients in small cohorts of non-selected patients with LM [54, 55]. Blocks can be partial or complete and can occur at the base of the brain, in the spinal subarachnoid space and over the cerebral convexities.

Recommendations:

- The diagnostic work-up should include cerebrospinal MRI. Brain MRI should include axial T₁-weighted, axial FLAIR, axial diffusion, axial T₂-weighted, post-gadolinium 3D T₁-weighted and post-gadolinium 3D FLAIR sequences. Spinal MRI should include post-gadolinium sagittal T₁-weighted sequences. Spine sagittal T₁-weighted sequences without contrast and sagittal fat suppression T₂-weighted sequences, combined with axial T₁-weighted images with contrast of regions of interest, may also be considered [EANO: III, C; ESMO: II, B].
- CSF flow studies should be considered for patients in whom CSF flow obstruction may be present, e.g. hydrocephalus, large nodules potentially reducing the CSF circulation on MRI, unexpected toxicity of intra-CSF treatment, and who are candidates for intra-CSF pharmacotherapy [EANO: IV, n/a; ESMO: IV, C].

CSF analysis

Non-diagnostic pathological findings upon routine CSF analysis are observed in more than 90% of LM patients and include increased opening pressure (> 200 mm H₂O) in 21%–42% [16, 44], increased leukocyte counts ($> 4/\text{mm}^3$) in 48%–77.5% [2, 10, 16, 44], elevated protein (> 50 mg/dL) in 56%–91% [2, 3, 10, 16, 44] and decreased glucose (< 60 mg/dL) in 22%–63% [2, 10, 16, 44]. However, only the identification of malignant cells in the CSF or in a leptomeningeal biopsy establishes the diagnosis of LM (gold standard). The results of CSF cytology studies are commonly qualitative and sensitivity is low, although specificity is high. In recent large cohorts of LM patients, CSF cytology was considered positive in 66%–90% [3]. CSF cytology should be reported as:

1. positive, defined by the presence of malignant cells in the CSF;

2. equivocal, corresponding to the detection of ‘suspicious’ or ‘atypical’ cells in the CSF; or
3. negative, defined as the absence of malignant or equivocal cells in the CSF.

A distinction of suspicious and atypical as proposed by the LANO group [1] is difficult to use in clinical practice. Staining of neoplastic cells for specific alterations such as the HER2 protein in breast cancer or BRAF^{V600E} protein in melanoma by immunocytochemistry may be useful in selected equivocal cases. The following simple measures may improve the sensitivity of CSF studies: obtaining sufficient volumes of CSF (ideally > 10 mL, but at least 5 mL), processing CSF within 30 min after sampling and avoiding haemorrhagic contamination [1, 56–58]. A higher sensitivity was reported with thin-layer preparations (Thinprep) than with cytospin-coupled Wright–Giemsa stains [59]. In patients suspected of having LM, CSF analysis should be carried out under optimal conditions. If the first CSF analysis is negative, a second lumbar puncture should be carried out under optimised conditions as outlined above, potentially increasing the sensitivity to 80%. The yield of further CSF assessments remains doubtful. CSF fixation in dedicated tubes as established for haematological disorders [60], such as ethylenediaminetetraacetic acid (EDTA) CSF sample storage tubes or CellSave™ preservative tubes, may diminish the need for rapid processing of the sample, but reports on the validation of this approach for solid tumours are lacking.

Novel techniques using epithelial cell adhesion molecule (EPCAM) antibodies or other tumour-specific antibody-covered magnetic nanoparticles to identify circulating tumour cells have shown promising results using various adaptations of the device initially designed for peripheral blood studies, combined with flow cytometry or tumour marker immunofluorescent *in situ* hybridisation (TM-iFISH). Such approaches may improve the sensitivity for tumour cell detection in the CSF but need validation in prospective studies [45, 61–67]. Genomic alterations can be detected in the CSF by micro-arrays [68], digital or real-time polymerase chain reaction (qPCR) and targeted amplicon sequencing, and whole exome sequencing [69–72]. Yet, there are still insufficient data to substitute a positive CSF cytology by the detection in the CSF of tumour-specific mutations at DNA level, e.g. BRAF^{V600E} or EGFR^{T790M}. It remains unclear whether tumour DNA detection in the CSF compartment always reflects the local presence of cells or whether this DNA may be derived from tumour cells circulating in the blood or even from distant extracerebral metastases. Future studies need to address the question of which quantitative cut-off of tumour DNA in CSF truly represents clinically relevant LM.

Numerous CSF biomarkers of LM have been explored in a tumour-specific manner, including β -glucuronidase, lactate dehydrogenase (LDH), β 2-microglobulin, cancer antigen (CA) 15-3, CA 125, CA 19-9, α -foetoprotein (AFP), neuron-specific enolase (NSE), or Cyfra 21-1 as direct tumour markers, or molecules thought to be involved in the metastatic process, specifically angiogenesis [e.g. vascular endothelial growth factor (VEGF), tissue plasminogen activator (tPA), stromal cell-derived factor (SDF)-1], migration and invasion [e.g. matrix metalloprotease (MMP)-2 and -9, cathepsins B, C and H], or adhesion and inflammation [e.g. C-X-C motif chemokine ligand 8 (CXCL-8)/interleukin-8, CXCL-10/interferon-inducible protein-10 and CCL18]. The role of these CSF biomarkers in clinical practice is limited, except for AFP or β -human chorionic gonadotropin (hCG) in patients with germ cell tumours, which are not covered by this guideline.

Recommendation:

- CSF studies with optimised analysis conditions must be carried out as part of the diagnostic work-up. One repeat lumbar puncture with optimised analysis conditions should be carried out in patients with suspected LM and initial negative or equivocal CSF studies [EANO: IV, n/a; ESMO: V, n/a].

Biopsy

Rarely, leptomeningeal biopsies may be required to confirm the diagnosis of LM. It may be useful when CSF cytology is repeatedly negative, when there is no history of cancer or if there are doubts about the cause of the clinical and imaging features and if therapeutic interventions are clinically indicated.

Diagnostic criteria for LM

The diagnosis of LM may be challenging, and several subtypes of syndromes collectively referred to as LM can be distinguished based on clinical findings, neuroimaging features and CSF analysis. In every case of suspected LM, it should be assessed whether any clinical abnormalities are causally related to LM detected by neuroimaging or CSF analysis. In most contemporary clinical trials, LM is diagnosed based on the detection of malignant cells in the CSF or on suggestive clinical and neuroimaging findings in patients with cancer. We propose to classify LM by using two major criteria:

1. Has the diagnosis been verified cytologically or histologically: yes (type I) or no (type II)?
2. What are the neuroimaging findings: linear leptomeningeal disease (type A), nodular leptomeningeal disease (type B), both (type C) or neither nor, e.g. no neuroimaging evidence of LM except possibly hydrocephalus (type D)? Type C should be assigned if the less prevalent phenotype (A or B) still accounts for an estimated disease burden of at least 20%.

Based on these considerations, the likelihood of LM can be assigned ‘confirmed’, ‘probable’, ‘possible’ or ‘no evidence for’ (Table 2). This classification provides guidance when to treat with relative confidence (‘confirmed’, ‘probable’) and when to reconsider intensified diagnostic efforts at establishing a firm

diagnosis (‘possible’, ‘no evidence for’). Patients meeting criteria for ‘no evidence for’ should not receive LM-directed tumour-specific treatment, but should receive a follow-up evaluation if the clinical suspicion of LM remains. Furthermore, we propose that clinical trials should only enrol patients with confirmed or probable LM, and should stratify for this certainty level of diagnosis.

Therapeutic strategies

The aim of treatment of LM is to prolong survival with acceptable quality of life, and to prevent or delay neurological deterioration. Several tumour-specific approaches can be used in isolation or combination. Recommendations for the treatment modalities for LM described below are not supported by data from randomised clinical trials; they are based on uncontrolled case series and expert opinion and current management strategies vary widely across Europe [73].

Pharmacotherapy: general considerations

Based on the assumption that intravenous (i.v.) antitumour agents will distribute in the same way as i.v. administered contrast agents, there is *a priori* no reason to believe that systemic pharmacotherapy for contrast-enhancing manifestations of LM should be less efficient than for other systemic manifestations of cancer. Moreover, increased CSF protein levels in most LM patients confirm that the blood–CSF barrier is commonly disrupted in LM and that there must be, therefore, increased levels of systemically administered drugs in the CSF of most patients with LM. However, floating tumour cells in the CSF in the setting of little or no blood–CSF barrier dysfunction or diffuse leptomeningeal or ependymal spread not yet accompanied by blood–brain barrier dysfunction may be poorly covered by systemic pharmacotherapy. Importantly, in the absence of blood–CSF barrier disturbances, drug distribution into the CSF depends mainly on drug transport across the choroid plexus and not across the blood–brain barrier [74]. No specific prospective trials have been reported on systemic treatment of LM, but retrospective series suggest some activity of systemic chemotherapy [75–77]. As there

Table 2. Diagnostic criteria for LM

	Cytology/biopsy	MRI	Confirmed	Probable ^a	Possible ^a	Lack of evidence
Type I: positive CSF cytology or biopsy	IA +	Linear	yes	n/a	n/a	n/a
	IB +	Nodular	yes	n/a	n/a	n/a
	IC +	Linear + nodular	yes	n/a	n/a	n/a
	ID +	Normal	yes	n/a	n/a	n/a
Type II: clinical findings and neuroimaging only	IIA – or equivocal	Linear	n/a	With typical clinical signs	Without typical clinical signs	n/a
	IIB – or equivocal	Nodular	n/a	With typical clinical signs	Without typical clinical signs	n/a
	IIC – or equivocal	Linear + nodular	n/a	With typical clinical signs	Without typical clinical signs	n/a
	IID – or equivocal	Normal	n/a	n/a	With typical clinical signs	Without typical clinical signs

Type A: LM with typical linear MRI abnormalities; Type B: LM with nodular disease only as type B; Type C: LM with both linear and nodular disease; Type D: LM without MRI abnormalities except possibly hydrocephalus.

^aRequires a history of cancer.

+, positive; –, negative; CSF, cerebrospinal fluid; LM, leptomeningeal metastasis; MRI, magnetic resonance imaging; n/a, not applicable.

Downloaded from https://academic.oup.com/annonc/article-abstract/28/suppl_4/iv84/3958155 by guest on 03 December 2019

are very limited data on the efficacy of targeted agents in LM, it remains uncertain whether these agents improve the prognosis of LM.

As for patients with brain metastasis [78], the best systemic treatment of LM is determined by the primary tumour, its molecular characteristics or the molecular characteristics of tumour cells of the CSF (when available) and prior treatment of the underlying malignancy.

LM from breast cancer

Common treatments administered in breast cancer patients with CNS metastases include capecitabine, cyclophosphamide, 5-fluorouracil (5-FU), methotrexate (MTX), vincristine, cisplatin, etoposide, vinorelbine and gemcitabine. No trial has specifically evaluated the role of trastuzumab in treating brain metastasis; however, a clinical benefit has been reported in patients with HER2-positive tumours treated for newly diagnosed brain metastasis [79, 80]. The efficacy of lapatinib was limited in brain metastasis patients when used alone [81–83], but promising when combined with capecitabine [82–86]. Only very limited data are available on the efficacy of trastuzumab-emtansine (T-DM1) in treating brain metastasis [87–89].

There are hardly any systematic studies of LM treatment in patients with breast cancer [90]. A concordance of 94% has been reported between the HER2 status of primary tumours and the tumour cells in the CSF [91]. In HER2-positive tumours with LM, anti-HER2 treatment in combination with chemotherapy should be considered. More data are also needed on the efficacy of bevacizumab in combination with various chemotherapies in LM patients [92]. Occasional responses of LM have been reported with hormonal agents. However, tumours are often resistant to hormonal therapy at the time of LM diagnosis.

LM from lung cancer

A platinum based-combination (including pemetrexed, gemcitabine, paclitaxel or vinorelbine for non-squamous and unselected NSCLC, respectively) can be chosen for treating brain metastasis from lung cancer [93, 94]. The addition of bevacizumab to classical chemotherapy might be beneficial for the treatment of brain metastasis in NSCLC [95].

EGFR mutations are observed in 11% of the Caucasian population with lung cancer [96] and predict benefit from first- (gefitinib, erlotinib) and second-generation (afatinib) EGFR tyrosine kinase inhibitors (TKIs) [13, 14, 16, 18, 29, 97–101], as well as the third-generation inhibitor osimertinib in the case of TKI resistance [102]. In several small cohorts, a preservation of the EGFR status was noted in the CSF relative to the primary tumour [18, 70, 72, 98]. Erlotinib may achieve higher CSF concentrations than gefitinib [103]. New EGFR TKIs such as osimertinib have shown promising results in a phase I trial on LM in patients who had progressed on prior EGFR TKI therapy [104]. Combinations of EGFR TKIs with other agents await exploration.

ALK rearrangements and *MET* mutations are found in 3%–5% and 4% of NSCLC, respectively. Crizotinib, which targets ALK, proto-oncogene tyrosine-protein kinase (ROS) and MET, represents the first targeted option for ALK-rearranged NSCLC patients [105]. Ceritinib, alectinib, lorlatinib or brigatinib may be

used after progression under crizotinib according to expert opinion. Accumulating evidence suggests a better CNS penetration of these compounds; however, only a few reports on the efficacy of second- or third-generation TKIs on LM are available [106]. *HER2*, *MET* and *BRAF* mutations as well as *RET* and *ROS* rearrangement have rarely been reported in lung cancer patients with LM. Appropriate inhibitors could represent therapeutic options once such a target has been identified. Only preliminary data are available on the efficacy of anti-programmed cell death 1 (PD-1) agents such as nivolumab [107, 108] or pembrolizumab [109] or anti-PD ligand 1 such as atezolizumab [110] in NSCLC patients with brain metastasis [111]. Data on the efficacy of immunotherapy for brain metastasis or LM are limited because such patients are commonly excluded from clinical trials.

LM from melanoma

Systemic chemotherapy using classical agents such as temozolomide, dacarbazine or fotemustine has only limited efficacy in melanoma patients with brain metastasis or LM. Ipilimumab, an antibody to anti-cytotoxic T-lymphocyte antigen 4, has shown efficacy in patients with brain metastasis [112, 113]. Anti-PD-1 antibodies have shown activity against extracerebral disease. However, only preliminary data are available for brain metastasis [111].

BRAF mutations are observed in 40%–60% of melanomas and a concordance of *BRAF* status of 100% has been observed between primary tumour and brain metastasis [114]. Responses have been reported in brain metastasis or LM patients with BRAF inhibitors such as vemurafenib [115, 116] or dabrafenib [117]. Although some emerging approaches have shown promising results in the control of extracerebral disease, only limited data are available on the efficacy of MAPK/ERK kinase (MEK) inhibitors (trametinib, selumetinib, pimarsertib) or the combination of BRAF and MEK inhibitors (dabrafenib + trametinib, vemurafenib + cobimetinib) in patients with CNS metastases or, specifically, LM from melanoma [20].

Other solid tumours

No specific data are available for the treatment of LM caused by other tumours, and treatments should be selected according to the primary tumour and its prior treatment.

High-dose systemic chemotherapy

Cytotoxic CSF concentrations of MTX, cytarabine or thiotriethylenephosphoramidate (thioTEPA) may be achieved using high-dose systemic administration, and these agents have induced responses in LM from various solid tumours [76, 118–120]. The major limitations of these approaches are haematological toxicity and their incompatibility with other systemic regimens potentially needed for the control of systemic disease.

Recommendation:

- Systemic pharmacotherapy based on primary tumour and previous treatment should be considered for most patients with type B/C LM [EANO: IV, n/a; ESMO: V, n/a].

Intra-CSF pharmacotherapy

Although no randomised trial has demonstrated that intra-CSF chemotherapy prolongs survival in LM patients, intra-CSF pharmacotherapy is used by the majority of physicians treating LM patients across Europe [73]. Due to its limited penetration into solid tumour lesions, e.g. up to 1–3 mm [121, 122], intra-CSF pharmacotherapy is mainly considered for patients with type A LM and a significant tumour cell load in the CSF (Table 2). Furthermore, intra-CSF pharmacotherapy should not be administered to patients with symptomatic hydrocephalus who require ventriculoperitoneal shunt placement or with a ventricular device without on/off option.

When intra-CSF pharmacotherapy is used, the administration may be done through repeated lumbar punctures or preferably through a subgaleal reservoir and intraventricular catheter. An equivalent or larger volume of CSF should be removed before each intra-CSF injection. After lumbar injection, patients should remain in a flat position for 1 h [123].

The conceptual advantages of the ventricular route include the certainty that the drug is not delivered into the epidural or subdural space instead of the CSF compartment, a more uniform distribution of the agent, greater patient comfort and a faster procedure, which improves compliance and safety of drug administration. The latter is particularly true for patients requiring anticoagulation [124–126]. The safety of ventricular devices has been shown in several cohorts of patients using different technologies and several devices, but careful handling is required to ensure aseptic puncture and drug application to minimise the risk of infectious complications [126–128]. The best surgical procedure has to be defined by the neurosurgeon in charge of the patient. No benefit of ventricular versus lumbar route has been demonstrated; however, a longer progression-free survival for MTX was observed in a sub-study of a randomised trial using the ventricular route. In contrast, there was no significant difference using liposomal cytarabine, presumably due to the different half-lives of these agents [124]. New approaches such as ventriculo-lumbar perfusion are interesting, but require further study [129].

Three agents are commonly used for the intrathecal treatment of LM: MTX, cytarabine, including liposomal cytarabine, or thioTEPA. Thus, the compounds routinely used for intra-CSF treatment do not have a key role as single agents for systemic treatment of most common cancers causing LM. Different schedules have been proposed for these agents, without consensus on optimal dose, frequency of administration or optimal duration of treatment (Table 3). No intra-CSF agent has shown a significant survival advantage over another [130, 131]. Combined intra-CSF agents have not demonstrated superiority over single intra-CSF agents [132], yet, longer time to neurological progression was reported in LM patients with liposomal cytarabine than in those patients treated with MTX [131]. Toxicities of the various intra-CSF agents differed. More mucositis or neurological complications such as headache were observed with MTX than with thioTEPA [130]. For MTX and liposomal cytarabine, Cancer and Leukemia Group B (CALGB)-expanded Common Toxicity Criteria treatment-related grade ≥ 3 toxicity was similar [131]. In a subanalysis, a greater quality-adjusted survival, measured by quality-adjusted time without symptoms or toxicity (Q-TWIST), was observed in patients treated with liposomal cytarabine than with MTX [133].

The efficacy and tolerance of intra-CSF trastuzumab in HER2-positive breast cancer is under evaluation in two trials (NCT01325207, NCT01373710). A small pooled analysis of 17 patients with HER2-positive breast cancer from 13 publications treated by intra-CSF trastuzumab reported clinical improvement in 69% of patients, with a median OS of 13.5 months [134].

A critical review of the randomised trials on LM, five of which enrolled patients with solid tumours [75, 125, 130–132] (Supplementary Table S1, available at *Annals of Oncology* online), all assessing the response to intra-CSF therapy, revealed a lack of standardisation for the evaluation of response and methodological limitations with respect to the type of tumour (haematological versus solid), baseline evaluation, response to treatment and evaluation of safety, and all experienced long times for accrual [46]. Moreover, all were open-label studies. Only cohort studies have been reported in recent years.

Table 3. Characteristics and schedules of administration of intra-CSF therapy

Agent	Description	Half-life in the CSF	Recommended schedules of administration	Prophylaxis of adverse events
Methotrexate	Folate anti-metabolite, cell cycle specific	4.5–8 h	10–15 mg twice weekly (total, 4 weeks), then 10–15 mg once weekly (total, 4 weeks) then 10–15 mg once monthly	Folinic acid rescue, 25 mg \times 6 h for 24 h starting 6 h after administration
Cytarabine	Pyrimidine nucleoside analogue, cell cycle specific	< 1 h	10 mg twice weekly (total, 4 weeks) then 10 mg once weekly (total, 4 weeks) then 10 mg once a month	None
Liposomal cytarabine	Pyrimidine nucleoside analogue, cell cycle specific	14–21 days	50 mg every 2 weeks (total, 8 weeks) then 50 mg once a month	Oral steroids, e.g. 6 mg dexamethasone equivalent daily (d1–d4)
ThioTEPA	Alkylating ethyleneimine compound, cell cycle non-specific	3–4 h	10 mg twice weekly (total, 4 weeks) then 10 mg once weekly (total, 4 weeks) then 10 mg once a month	None

CSF, cerebrospinal fluid; thioTEPA, thiotriethylenephosphoramidate.

One single trial tried to explore the value of adding intra-ventricular MTX to systemic therapy and involved-field radiotherapy (RT), but the trial was prematurely closed [75]. A total of 35 breast cancer patients with LM were evaluated based on clinical findings only. No differences for clinical response or OS were observed, but more treatment-related neurotoxicity, scored according to a local scale, was noted in the intra-CSF chemotherapy arm (47% versus 6%). The complication rate in the intra-CSF chemotherapy arm, with 18% of reservoir revisions, was also high compared with other cohorts (< 7.3% of reservoir revision) [126–128]. The role of adding intra-CSF chemotherapy using liposomal cytarabine to systemic therapy in breast cancer patients with LM is readdressed in an ongoing phase III trial (NCT01645839).

The optimal duration of intra-CSF treatment has also not been adequately explored. Most patients nowadays are treated until progression or for 1 year, if tolerated. In the absence of evidence from appropriate clinical trials, clinical symptoms and MRI and CSF findings, as well as tolerance of treatment, guide individual decisions on the duration of treatment. Notably, the role of persisting positive CSF cytology alone for decision-making regarding the continuation of treatment remains controversial [1].

Recommendations:

- Intra-CSF pharmacotherapy should be considered for most patients with type IA/C LM [EANO: IV, n/a; ESMO: V, n/a].
- Intra-CSF pharmacotherapy should be administered through the ventricular rather than lumbar route whenever feasible [EANO: IV, n/a; ESMO: V, n/a].

Radiotherapy

No randomised clinical trial to assess the efficacy and tolerance of RT in LM has been conducted. Focal RT administered in fractionated regimens such as involved-field or stereotactic RT or administered in single fractions (radiosurgery) can be used to treat nodular disease and symptomatic cerebral or spinal sites.

In exceptional cases, focal RT can be carried out for cauda equina syndrome or cranial nerve palsies after exclusion of other causes, even in the absence of corresponding MRI findings. The presence of CSF flow interruptions is associated with decreased survival [54, 55, 135]. Restoration of CSF flow obstruction can be obtained by focal RT in 30% of patients with spinal blocks and in 50% of patients with intracranial blocks [136] and has been proposed to reduce the toxicity from, and enhance the efficacy of, intra-CSF therapy.

Typical target volumes for RT in the presence of cranial neuropathies include, by expert consensus, the skull base, the interpeduncular cistern and the two first cervical vertebrae. Typical target volumes for RT in the presence of a cauda equina syndrome include the lumbosacral vertebrae. WBRT may be considered for extensive nodular or symptomatic linear LM or co-existing brain metastasis. Yet, no association of WBRT with survival was observed in retrospective studies of LM patients [13, 14, 15, 18, 28]. Cerebrospinal RT is rarely an option for adult patients with LM from solid cancers because of risk of bone marrow toxicity, enteritis and mucositis, and the usual co-existence of systemic disease. Concomitant craniospinal RT and systemic or intra-CSF treatment should be avoided to prevent severe toxicity, notably myelosuppression. Up to 20% of grade 3–4 adverse events have been reported in a phase II trial evaluating

concomitant intra-CSF MTX plus dexamethasone with focal RT for patients with LM from various solid tumours [137]. Intra-CSF administration of radioisotopes or radiolabelled monoclonal antibodies should be explored in the context of clinical trials.

Recommendations:

- Focal RT should be considered for circumscribed, notably symptomatic lesions [EANO: IV, n.a.; ESMO: V, n.a.].
- WBRT can be considered for extensive nodular or symptomatic linear LM [EANO: IV, n/a; ESMO: V, n/a].

Individualised approach to LM

Diagnosis and management of patients with LM should follow multidisciplinary tumour board recommendations throughout the disease course. The therapeutic strategy should consider general health and the neurological status of the patient, histological and molecular subtype of the primary cancer, extent and available therapeutic options for extra-CNS disease, clinical and imaging presentation of LM, and presence of concomitant brain metastasis. The therapeutic recommendations summarised in Figure 1 and Table 4 are largely based on retrospective cohort data or expert agreements and must be considered as having a low level of evidence. Randomised clinical trials with adapted methodology and standardised criteria for diagnosis and response are needed to better define the role of all therapeutic interventions in LM.

Monitoring and follow-up

No robust data are available and monitoring recommendations today are still based on consensus and expert opinion. The LANO group has made efforts to determine criteria to evaluate the response to treatment in LM patients [1] (Supplementary Table S2, available at *Annals of Oncology* online). Although the proposal by the LANO group remains controversial largely because of its complexity, we concur with the view that response should be evaluated according to a complete neurological assessment, a neuroimaging evaluation and standard CSF cytology. CSF parameters other than the detection of tumour cells are not considered (Table 5). Symptoms and signs related to concomitant brain metastasis, extracerebral progression, toxicity induced by treatments or concurrent diseases must not be considered for the evaluation of LM response. As most neurological deficits in LM patients are irreversible, the best anticipated clinical response is usually achievement of stable disease. A complete cerebrospinal MRI is required for the evaluation of response. During follow-up, MRI should preferably be repeated using the same scanner or at least a scanner of identical field strength (Table 1). Other imaging modalities such as MR spectroscopy, MR perfusion or PET have no role so far in the assessment of LM during follow-up. The LANO group has proposed an MRI grid for the assessment of radiographic response, which needs to be validated. Due to small volume and geometric complexity, a quantitative assessment is often not possible, and LM lesions may be difficult to measure reliably. Thus, it has been proposed to distinguish ‘measurable’ LM disease defined by at least one nodular lesion of more than 5 × 10 mm from ‘non-measurable’ disease which encompasses all

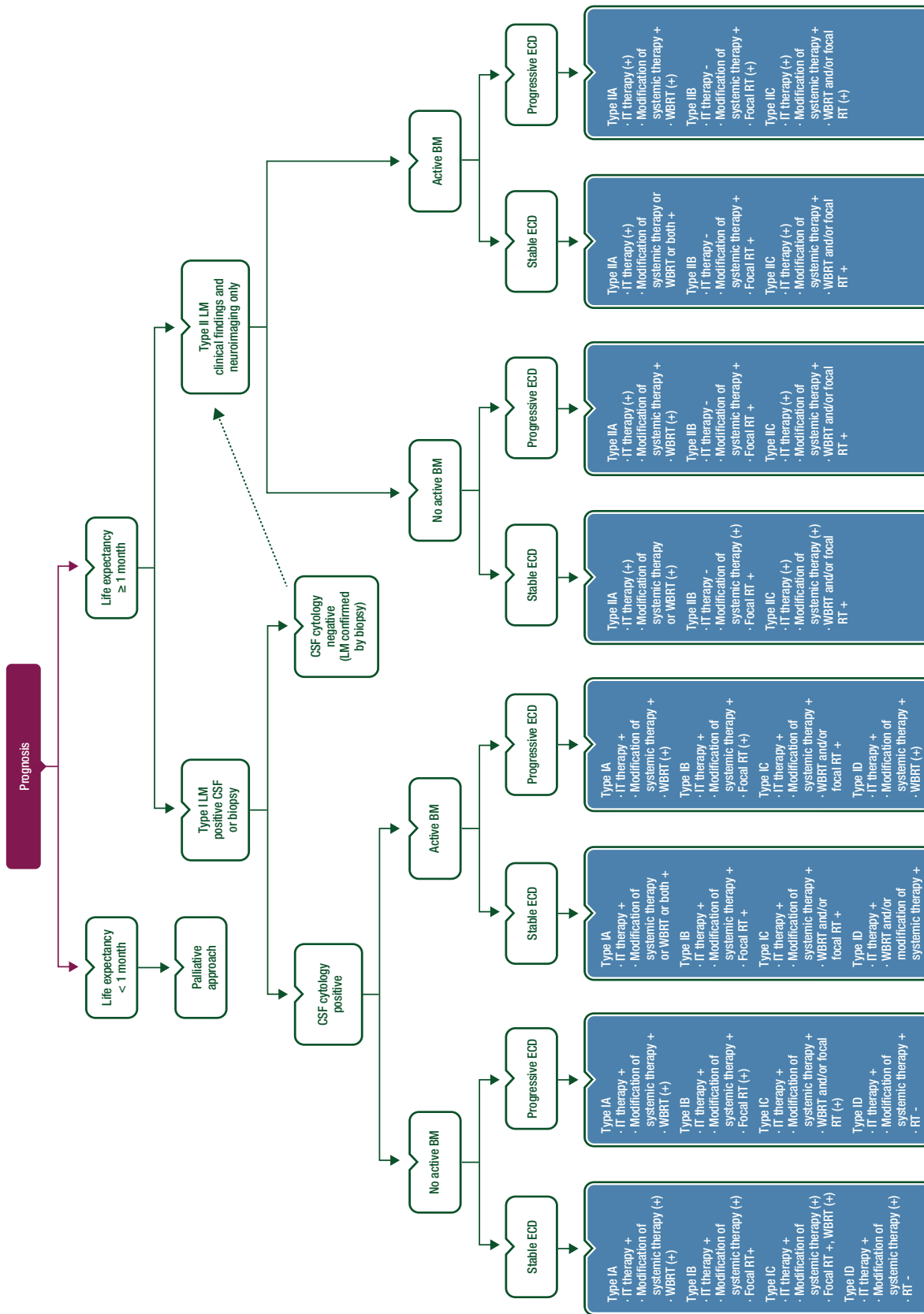


Figure 1. Therapeutic approach to LM.

This decision tree is based on expert agreement. When selecting therapeutic options, systemic pharmacotherapy should always be considered. A modification of systemic pharmacotherapy is recommended in patients with progressive extracranial disease as well as in patients with progressive BM, unless RT alone is a preferred option. Intra-CSF pharmacotherapy is recommended in case of floating tumour cell load in the CSF and is optional in case of linear metastatic meningeal disease. Intra-CSF pharmacotherapy is not recommended in patients with symptomatic hydrocephalus who require ventriculoperitoneal shunt placement or with a ventricular device without on/off option or in patients with nodular meningeal metastases only. Focal RT is recommended for the treatment of nodular disease and symptomatic metastatic cerebral or spinal sites. WBRT may be an option for extensive nodular or symptomatic linear LM or co-existing BM. Note that RT options refer to treatment of LM only. BM, brain metastases; CSF, cerebrospinal fluid; ECD, extracranial disease; IT, intrathecal; LM, leptomeningeal metastases; RT, radiotherapy; WBRT, whole brain radiotherapy; +, recommended; (+), optional; -, not recommended.

Table 4. Key recommendations for the diagnosis and treatment of LM from solid tumours

	EANO [146]		ESMO [147]	
	Level of evidence	Grade of recommendation	Level of evidence	Grade of recommendation
Diagnostic procedures				
LM should be considered in particular in patients with breast or lung cancer or melanoma who present with neurological symptoms or signs	III	C	III	B
Typical clinical signs of LM such as headache, nausea and vomiting, mental changes, gait difficulties, cranial nerve palsies with diplopia, visual disturbances, hearing loss, sensorimotor deficits of extremities and cauda equine syndrome, radicular, neck and back pain, notably in a patient with cancer, should alert clinicians to consider LM	IV	n/a	V	n/a
A detailed neurological examination using a standard evaluation form, e.g. as proposed by the LANO group, should be carried out at diagnosis	IV	n/a	V	n/a
The diagnostic work-up should include cerebrospinal MRI. Brain MRI should include axial T ₁ -weighted, axial FLAIR, axial diffusion, axial T ₂ -weighted, post-gadolinium 3D T ₁ -weighted and post-gadolinium 3D FLAIR sequences. Spinal MRI should include post-gadolinium sagittal T ₁ -weighted sequences. Spine sagittal T ₁ -weighted sequences without contrast and sagittal fat suppression T ₂ -weighted sequences, combined with axial T ₁ -weighted images with contrast of regions of interest, may also be considered	III	C	II	B
CSF flow studies should be considered for patients in whom CSF flow obstruction may be present, e.g. hydrocephalus, large nodules potentially reducing the CSF circulation on MRI, unexpected toxicity of intra-CSF treatment, and who are candidates for intra-CSF pharmacotherapy	IV	n/a	IV	C
CSF studies with optimised analysis conditions must be carried out as part of the diagnostic work-up. One repeat lumbar puncture with optimised analysis conditions should be carried out in patients with suspected LM and initial negative or equivocal CSF studies	IV	n/a	V	n/a
Therapeutic strategies				
Systemic pharmacotherapy based on primary tumour and previous treatment should be considered for most patients with type B/C LM	IV	n/a	V	n/a
Intra-CSF pharmacotherapy should be considered for most patients with type IA/C LM	IV	n/a	V	n/a
Intra-CSF pharmacotherapy should be administered through the ventricular rather than lumbar route whenever feasible	IV	n/a	V	n/a
Focal RT should be considered for circumscribed, notably symptomatic lesions	IV	n/a	V	n/a
WBRT can be considered for extensive nodular or symptomatic linear LM	IV	n/a	V	n/a
Monitoring and follow-up				
A detailed neurological examination using a standard evaluation form should be carried out every 2–3 months or at radiological progression or when new neurological symptoms or signs are reported	IV	n/a	V	n/a
Cerebrospinal MRI should be carried out every 2–3 months or at any instance of suspected clinical progression	IV	n/a	V	n/a
CSF studies should be carried out every 2–3 months in patients undergoing intra-CSF pharmacotherapy	IV	n/a	V	n/a
Level of evidence and grade of recommendation according to Brainin (EANO recommendations) or Dykewicz (ESMO recommendations) [146, 147]. CSF, cerebrospinal fluid; EANO, European Association of Neuro-Oncology; ESMO, European Society for Medical Oncology; FLAIR, fluid-attenuated inversion recovery; LANO, Leptomeningeal Assessment in Neuro-Oncology; LM, leptomeningeal metastasis; MRI, magnetic resonance imaging; n/a, not applicable; RT, radiotherapy; WBRT, whole brain radiotherapy.				

other MRI abnormalities [1]. Changes in size, but not changes in intensity of contrast enhancement, should be considered. Changes in hydrocephalus should be considered as part of the response evaluation in clinical practice, but were not included in the LANO

MRI grid. In clinical trials, concomitant brain or extradural spinal metastases are evaluated separately for response.

CSF cell counts could, in principle, be obtained specifically for tumour, as opposed to non-neoplastic cells, but this has

Table 5. EANO–ESMO response assessment in LM^a

Clinical	Imaging	CSF	Response determination	Action
Improved or stable	Improved	Improved or stable	Response	Continue treatment
Stable	Stable	Stable	Stable	Continue treatment
Worse	Improved or stable	Improved or stable	Suspicion of progression	Consider alternative neurological diagnoses or other reasons for clinical deterioration; change treatment only if there is no other explanation and if there is significant worsening of clinical signs for more than 2 weeks
Improved or stable	Improved or stable	Worse	Suspicion of progression, or progression in case of <i>de novo</i> appearance of tumour cells in the CSF ^b	Continue treatment, change treatment if appearance of tumour cells is confirmed on two consecutive CSF studies from the same CSF site (lumbar or ventricular) at least 4 weeks apart
Worse	Improved or stable	Worse	Suspicion of progression, or progression in case of <i>de novo</i> appearance of tumour cells in the CSF ^b	Consider alternative neurological diagnoses, continue treatment; change treatment if there is worsening of clinical signs for more than 2 weeks and if appearance of tumour cells is confirmed on two consecutive CSF studies from the same CSF site (lumbar or ventricular) at least 4 weeks apart
Improved or stable	Worse	Improved or stable	Progression	Change treatment
Improved or stable	Worse	Worse	Progression	Change treatment
Worse	Worse	Improved or stable or worse	Progression	Change treatment

^aDifferences from the LANO recommendations are illustrated in Supplementary Table S2, available at *Annals of Oncology* online.

^b*De novo* detection of tumour cells as an indicator of progressive disease requires that there were at least two adequately performed negative CSF analyses.

CSF, cerebrospinal fluid; EANO, European Association of Neuro-Oncology; ESMO, European Society for Medical Oncology; LANO, Leptomeningeal Assessment in Neuro-Oncology; LM, leptomeningeal metastasis.

remained challenging and would require more sophisticated techniques than commonly available. As discussed above, the proposal by the LANO group to classify the standard CSF cytology results into two groups of patients, negative or atypical, versus positive or suspicious, appears too complex. Three categories of positive, equivocal and negative seem to be more feasible in clinical practice (see above). A complete CSF cytological response requires a conversion of a previously positive to a negative CSF response maintained for at least 4 weeks. If only lumbar CSF was positive and the patient is treated through a ventricular reservoir, the CSF response cannot be evaluated unless further lumbar CSF samples are obtained. An unequivocal *de novo* appearance of malignant cells in the CSF after repeated negative CSF cytologies carried out under optimised conditions should be considered as progression and does not require a confirmatory analysis. In contrast, a change from negative to equivocal is not considered relevant for clinical decision-making. CSF cytology may remain positive in patients with stable or improved clinical or imaging features [138]. The levels of CSF protein, glucose or lactate, or novel biomarkers or new methodologies for the identification of tumour cells in the CSF have not been integrated into routine response determination at present.

Clinical, imaging and CSF evaluations should be carried out at baseline and at defined time points thereafter to assess the

response. Evaluations should be planned every 2 months for the first 6 months and every 3 months thereafter in stable patients, but should be carried out earlier whenever there is suspicion of progression based on clinical assessment.

Recommendations:

- A detailed neurological examination using a standard evaluation form should be carried out every 2–3 months or at radiological progression or when new neurological symptoms or signs are reported [EANO: IV, n/a; ESMO: V, n/a].
- Cerebrospinal MRI should be carried out every 2–3 months or at any instance of suspected clinical progression [EANO: IV, n/a; ESMO: V, n/a].
- CSF studies should be carried out every 2–3 months in patients undergoing intra-CSF pharmacotherapy [EANO: IV, n/a; ESMO: V, n/a].

Supportive care

Although this guideline does not aim at comprehensively describing palliative and supportive care, a few points deserve consideration. The role of steroids has not been specifically studied in LM patients, notwithstanding their role for associated brain metastasis,

Table 6. Levels of evidence and grades of recommendation for a therapeutic intervention (using the European Federation of Neurological Societies criteria as recommended by EANO) [146]**Evidence classification**

Class I: An adequately powered prospective, randomised, controlled clinical trial with masked outcome assessment in a representative population or an adequately powered systematic review of prospective randomised controlled clinical trials with masked outcome assessment in representative populations. The following are required:

- Randomisation concealment
- Primary outcome(s) is/are clearly defined
- Exclusion/inclusion criteria are clearly defined
- Adequate accounting for dropouts and crossovers with numbers sufficiently low to have minimal potential for bias
- Relevant baseline characteristics are presented and substantially equivalent among treatment groups or there is appropriate statistical adjustment for differences

Class II: Prospective matched-group cohort study in a representative population with masked outcome assessment that meets a–e above or a randomised, controlled trial in a representative population that lacks one criteria a–e

Class III: All other controlled trials (including well-defined natural history controls or patients serving as own controls) in a representative population, where outcome assessment is independent of patient treatment

Class IV: Evidence from uncontrolled studies, case series, case reports or expert opinion

Rating of recommendations

Level A rating (established as effective, ineffective or harmful) requires at least one convincing class I study or at least two consistent, convincing class II studies

Level B rating (probably effective, ineffective or harmful) requires at least one convincing class II study or overwhelming class III evidence

Level C (possibly effective, ineffective or harmful) rating requires at least two convincing class III studies

Reprinted from [146] by permission of European Journal of Neurology. Copyright © 2004, John Wiley and Sons. EANO, European Association of Neuro-Oncology.

chemical meningitis or other systemic complications of cancer. Steroids may also alleviate meningeal irritation and radicular pain. When required clinically, the lowest dose of steroids should be used for the shortest time possible. Seizures should be managed using drugs that do not interact with systemic treatments. Primary prophylaxis is not recommended [139, 140]. Ventriculoperitoneal shunting may provide durable relief from symptomatic hydrocephalus [141–144]. National and institutional guidelines may provide further guidance [145].

Outlook

Guidelines reflect knowledge and consensus at a given timepoint. Updates on these recommendations will be announced on the website of EANO (www.eano.eu) and ESMO (www.esmo.org).

Randomised trials based on well-defined diagnostic and inclusion criteria, in appropriately selected sub-groups of LM patients,

Table 7. Levels of evidence and grades of recommendation for a diagnostic measure (using the European Federation of Neurological Societies criteria as recommended by EANO) [146]**Evidence classification**

Class I: A prospective study in a broad spectrum of persons with the suspected condition, using a 'gold standard' for case definition, where the test is applied in a blinded evaluation, and enabling the assessment of appropriate tests of diagnostic accuracy

Class II: A prospective study of a narrow spectrum of persons with the suspected condition, or a well-designed retrospective study of a broad spectrum of persons with an established condition (by 'gold standard') compared with a broad spectrum of controls, where test is applied in a blinded evaluation, and enabling the assessment of appropriate tests of diagnostic accuracy

Class III: Evidence provided by a retrospective study where either persons with the established condition or controls are of a narrow spectrum, and where test is applied in a blinded evaluation

Class IV: Any design where test is not applied in blinded evaluation OR evidence provided by expert opinion alone or in descriptive case series (without controls)

Rating of recommendations

Level A rating (established as useful/predictive or not useful/predictive) requires at least one convincing class I study or at least two consistent, convincing class II studies

Level B rating (established as probably useful/predictive or not useful/predictive) requires at least one convincing class II study or overwhelming class III evidence

Level C rating (established as possibly useful/predictive or not useful/predictive) requires at least two convincing class III studies

Reprinted from [146] by permission of European Journal of Neurology. Copyright © 2004, John Wiley and Sons. EANO, European Association of Neuro-Oncology.

enriched for molecular genetic signatures where feasible, and with adequate criteria of evaluation are required to improve the outcome of LM in a primary cancer-specific manner. Important questions to address include the role of intrathecal pharmacotherapy and of novel systemic therapies, notably targeted agents and immunotherapy.

Methodology

References were identified through searches of PubMed with the search terms 'leptomeningeal metastasis', 'neoplastic meningitis', 'intrathecal', 'intra-CSF', 'CNS', 'brain', 'metastasis', 'trial', 'clinical', 'radiotherapy' and 'chemotherapy' in various combinations from 1 January 1976 to 30 November 2016, because of the paucity of data on this topic. Articles were also identified through searches of the authors' own files. Only papers in English were reviewed. Data available only in Abstract form were only exceptionally included. The final reference list was generated by consensus of the authors and based on originality and relevance to the broad scope of this guideline. Levels of evidence and grades of recommendation were applied using the European Federation of Neurological Societies criteria as recommended by EANO (Tables 6 and 7) [146] as well as using an adapted version of the

Table 8. Levels of evidence and grades of recommendation as recommended by ESMO (adapted from the Infectious Diseases Society of America–United States Public Health Service Grading System^a)

Levels of evidence	
I	Evidence from at least one large randomised, controlled trial of good methodological quality (low potential for bias) or meta-analyses of well-conducted randomised trials without heterogeneity
II	Small randomised trials or large randomised trials with a suspicion of bias (lower methodological quality) or meta-analyses of such trials or of trials demonstrated heterogeneity
III	Prospective cohort studies
IV	Retrospective cohort studies or case–control studies
V	Studies without control group, case reports, expert opinions
Grades of recommendation	
A	Strong evidence for efficacy with a substantial clinical benefit, strongly recommended
B	Strong or moderate evidence for efficacy but with a limited clinical benefit, generally recommended
C	Insufficient evidence for efficacy or benefit does not outweigh the risk or the disadvantages (adverse events, costs, . . .), optional
D	Moderate evidence against efficacy or for adverse outcome, generally not recommended
E	Strong evidence against efficacy or for adverse outcome, never recommended

^aBy permission of the Infectious Diseases Society of America [147].

Infectious Disease Society of America–United States Public Health Service Grading System as recommended by ESMO (Table 8) [147]. Statements without grading were considered justified standard clinical practice by the experts. This manuscript has been subjected to an anonymous peer review process.

Funding

No external funding has been received for the preparation of these guidelines. Production costs have been covered by ESMO from central funds.

Disclosure

ELR has received research support from Mundipharma and Amgen. MW has received research grants from Acceleron, Actelion, Bayer, Isarna, MSD, Merck EMD, Novocure, Piquor and Roche and honoraria for lectures or advisory board participation or consulting from Bristol-Myers Squibb, Celldex, Immunocellular Therapeutics, Isarna, Magforce, MSD, Merck EMD, Northwest Biotherapeutics, Novocure, Pfizer, Roche, Teva and Tocagen. MVdB has received research support from BBB therapeutics. EdA has received advisory board from Roche; travels grant from Roche and GlaxoSmithKline; research grant from Roche. WW has received research support from Pfizer, Apogenix, MSD and Roche and has reported being a member of the speaker's bureau of Bristol-Myers Squibb and MSD. MP has received research support from Böhringer-Ingelheim, GlaxoSmithKline,

Merck Sharp & Dohme and Roche and honoraria for lectures, consultation or advisory board participation from Bristol-Myers Squibb, Novartis, Gerson Lehrman Group, CMC Contrast, GlaxoSmithKline, Mundipharma, Roche and AstraZeneca. DB, RH, TB, SP, CW, WW, PW and RR have declared no potential conflicts of interest.

References

- Chamberlain M, Junck L, Brandsma D et al. Leptomeningeal metastases: a RANO proposal for response criteria. *Neuro Oncol* 2017; 19: 484–492.
- Rudnicka H, Niwińska A, Murawska M. Breast cancer leptomeningeal metastasis—the role of multimodality treatment. *J Neurooncol* 2007; 84: 57–62.
- Gauthier H, Guilhaume MN, Bidard FC et al. Survival of breast cancer patients with meningeal carcinomatosis. *Ann Oncol* 2010; 21: 2183–2187.
- Lee S, Ahn HK, Park YH et al. Leptomeningeal metastases from breast cancer: intrinsic subtypes may affect unique clinical manifestations. *Breast Cancer Res Treat* 2011; 129: 809–817.
- de Azevedo CR, Cruz MR, Chinen LT et al. Meningeal carcinomatosis in breast cancer: prognostic factors and outcome. *J Neurooncol* 2011; 104: 565–572.
- Lara-Medina F, Crismatt A, Villarreal-Garza C et al. Clinical features and prognostic factors in patients with carcinomatous meningitis secondary to breast cancer. *Breast J* 2012; 18: 233–241.
- Meattini I, Livi L, Saieva C et al. Prognostic factors and clinical features in patients with leptomeningeal metastases from breast cancer: a single center experience. *J Chemother* 2012; 24: 279–284.
- Kim HJ, Im SA, Keam B et al. Clinical outcome of central nervous system metastases from breast cancer: differences in survival depending on systemic treatment. *J Neurooncol* 2012; 106: 303–313.
- Niwińska A, Rudnicka H, Murawska M. Breast cancer leptomeningeal metastasis: propensity of breast cancer subtypes for leptomeninges and the analysis of factors influencing survival. *Med Oncol* 2013; 30: 408.
- Yust-Katz S, Garcarena P, Liu D et al. Breast cancer and leptomeningeal disease (LMD): hormone receptor status influences time to development of LMD and survival from LMD diagnosis. *J Neurooncol* 2013; 114: 229–235.
- Le Rhun E, Taillibert S, Zairi F et al. A retrospective case series of 103 consecutive patients with leptomeningeal metastasis and breast cancer. *J Neurooncol* 2013; 113: 83–92.
- Niwińska A, Rudnicka H, Murawska M. Breast cancer leptomeningeal metastasis: the results of combined treatment and the comparison of methotrexate and liposomal cytarabine as intra-cerebrospinal fluid chemotherapy. *Clin Breast Cancer* 2015; 15: 66–72.
- Morris PG, Reiner AS, Szenberg OR et al. Leptomeningeal metastasis from non-small cell lung cancer: survival and the impact of whole brain radiotherapy. *J Thorac Oncol* 2012; 7: 382–385.
- Park JH, Kim YJ, Lee JO et al. Clinical outcomes of leptomeningeal metastasis in patients with non-small cell lung cancer in the modern chemotherapy era. *Lung Cancer* 2012; 76: 387–392.
- Gwak HS, Joo J, Kim S et al. Analysis of treatment outcomes of intraventricular chemotherapy in 105 patients for leptomeningeal carcinomatosis from non-small-cell lung cancer. *J Thorac Oncol* 2013; 8: 599–605.
- Lee SJ, Lee JI, Nam DH et al. Leptomeningeal carcinomatosis in non-small-cell lung cancer patients: impact on survival and correlated prognostic factors. *J Thorac Oncol* 2013; 8: 185–191.
- Riess JW, Nagpal S, Iv M et al. Prolonged survival of patients with non-small-cell lung cancer with leptomeningeal carcinomatosis in the modern treatment era. *Clin Lung Cancer* 2014; 15: 202–206.
- Kuiper JL, Hendriks LE, van der Wekken AJ et al. Treatment and survival of patients with EGFR-mutated non-small cell lung cancer and leptomeningeal metastasis: a retrospective cohort analysis. *Lung Cancer* 2015; 89: 255–261.
- Harstad L, Hess KR, Groves MD. Prognostic factors and outcomes in patients with leptomeningeal melanomatosis. *Neuro Oncol* 2008; 10: 1010–1018.

20. Geukes Foppen MH, Brandsma D, Blank CU et al. Targeted treatment and immunotherapy in leptomeningeal metastases from melanoma. *Ann Oncol* 2016; 27: 1138–1142.
21. Roelz R, Reinacher P, Jabbarli R et al. Surgical ventricular entry is a key risk factor for leptomeningeal metastasis of high grade gliomas. *Sci Rep* 2015; 5: 17758.
22. Ahn JH, Lee SH, Kim S et al. Risk for leptomeningeal seeding after resection for brain metastases: implication of tumor location with mode of resection. *J Neurosurg* 2012; 116: 984–993.
23. Elliott JP, Keles GE, Waite M et al. Ventricular entry during resection of malignant gliomas: effect on intracranial cerebrospinal fluid tumor dissemination. *J Neurosurg* 1994; 80: 834–839.
24. Norris LK, Grossman SA, Olivi A. Neoplastic meningitis following surgical resection of isolated cerebellar metastasis: a potentially preventable complication. *J Neurooncol* 1997; 32: 215–223.
25. van der Ree TC, Dippel DW, Avezaat CJ et al. Leptomeningeal metastasis after surgical resection of brain metastases. *J Neurol Neurosurg Psychiatry* 1999; 66: 225–227.
26. Suki D, Hatiboglu MA, Patel AJ et al. Comparative risk of leptomeningeal dissemination of cancer after surgery or stereotactic radiosurgery for a single supratentorial solid tumor metastasis. *Neurosurgery* 2009; 64: 664–674; discussion 674–676.
27. Johnson MD, Avkshtol V, Baschnagel AM et al. Surgical resection of brain metastases and the risk of leptomeningeal recurrence in patients treated with stereotactic radiosurgery. *Int J Radiat Oncol Biol Phys* 2016; 94: 537–543.
28. Abouharb S, Ensor J, Loghin ME et al. Leptomeningeal disease and breast cancer: the importance of tumor subtype. *Breast Cancer Res Treat* 2014; 146: 477–486.
29. Liao BC, Lee JH, Lin CC et al. Epidermal growth factor receptor tyrosine kinase inhibitors for non-small-cell lung cancer patients with leptomeningeal carcinomatosis. *J Thorac Oncol* 2015; 10: 1754–1761.
30. Matsumoto S, Takahashi K, Iwakawa R et al. Frequent EGFR mutations in brain metastases of lung adenocarcinoma. *Int J Cancer* 2006; 119: 1491–1494.
31. Iuchi T, Shingyoji M, Itakura M et al. Frequency of brain metastases in non-small-cell lung cancer, and their association with epidermal growth factor receptor mutations. *Int J Clin Oncol* 2015; 20: 674–679.
32. Gainor JF, Ou SH, Logan J et al. The central nervous system as a sanctuary site in ALK-positive non-small-cell lung cancer. *J Thorac Oncol* 2013; 8: 1570–1573.
33. Lee DW, Lee KH, Kim JW, Keam B. Molecular targeted therapies for the treatment of leptomeningeal carcinomatosis: current evidence and future directions. *Int J Mol Sci* 2016; 17: pii E1074.
34. Shaw AT, Kim DW, Nakagawa K et al. Crizotinib versus chemotherapy in advanced ALK-positive lung cancer. *N Engl J Med* 2013; 368: 2385–2394.
35. Clarke JL, Perez HR, Jacks LM et al. Leptomeningeal metastases in the MRI era. *Neurology* 2010; 74: 1449–1454.
36. Oechsle K, Lange-Brock V, Kruell A et al. Prognostic factors and treatment options in patients with leptomeningeal metastases of different primary tumors: a retrospective analysis. *J Cancer Res Clin Oncol* 2010; 136: 1729–1735.
37. Herrlinger U, Wiendl H, Renninger M et al. Vascular endothelial growth factor (VEGF) in leptomeningeal metastasis: diagnostic and prognostic value. *Br J Cancer* 2004; 91: 219–224.
38. Clatot F, Philippin-Lauridant G, Ouvrier MJ et al. Clinical improvement and survival in breast cancer leptomeningeal metastasis correlate with the cytologic response to intrathecal chemotherapy. *J Neurooncol* 2009; 95: 421–426.
39. Hyun JW, Jeong IH, Joung A et al. Leptomeningeal metastasis: clinical experience of 519 cases. *Eur J Cancer* 2016; 56: 107–114.
40. Boyle R, Thomas M, Adams JH. Diffuse involvement of the leptomeninges by tumour—a clinical and pathological study of 63 cases. *Postgrad Med J* 1980; 56: 149–158.
41. Gonzalez-Vitale JC, Garcia-Bunuel R. Meningeal carcinomatosis. *Cancer* 1976; 37: 2906–2911.
42. Kokkoris CP. Leptomeningeal carcinomatosis. How does cancer reach the pia-arachnoid? *Cancer* 1983; 51: 154–160.
43. Küsters-Vandeveldel HV, Küsters B, van Engen-van Grunsven AC et al. Primary melanocytic tumors of the central nervous system: a review with focus on molecular aspects. *Brain Pathol* 2015; 25: 209–226.
44. Kwon J, Chie EK, Kim K et al. Impact of multimodality approach for patients with leptomeningeal metastases from solid tumors. *J Korean Med Sci* 2014; 29: 1094–1101.
45. Nayak L, DeAngelis LM, Brandes AA et al. The Neurologic Assessment in Neuro-Oncology (NANO) scale: a tool to assess neurologic function for integration into the Response Assessment in Neuro-Oncology (RANO) criteria. *Neuro Oncol* 2017; 19: 625–635.
46. Chamberlain M, Soffiotti R, Raizer J et al. Leptomeningeal metastasis: a Response Assessment in Neuro-Oncology critical review of endpoints and response criteria of published randomized clinical trials. *Neuro Oncol* 2014; 16: 1176–1185.
47. Freilich RJ, Krol G, DeAngelis LM. Neuroimaging and cerebrospinal fluid cytology in the diagnosis of leptomeningeal metastasis. *Ann Neurol* 1995; 38: 51–57.
48. Singh SK, Agris JM, Leeds NE, Ginsberg LE. Intracranial leptomeningeal metastases: comparison of depiction at FLAIR and contrast-enhanced MR imaging. *Radiology* 2000; 217: 50–53.
49. Straathof CS, de Bruin HG, Dippel DW, Vecht CJ. The diagnostic accuracy of magnetic resonance imaging and cerebrospinal fluid cytology in leptomeningeal metastasis. *J Neurol* 1999; 246: 810–814.
50. Zeiser R, Burger JA, Bley TA et al. Clinical follow-up indicates differential accuracy of magnetic resonance imaging and immunocytology of the cerebral spinal fluid for the diagnosis of neoplastic meningitis—a single centre experience. *Br J Haematol* 2004; 124: 762–768.
51. Singh SK, Leeds NE, Ginsberg LE. MR imaging of leptomeningeal metastases: comparison of three sequences. *AJNR Am J Neuroradiol* 2002; 23: 817–821.
52. Mahendru G, Chong V. Meninges in cancer imaging. *Cancer Imaging* 2009; 9: Spec No A:S14-S21.
53. Lombardi G, Zustovich F, Farina P et al. Neoplastic meningitis from solid tumors: new diagnostic and therapeutic approaches. *Oncologist* 2011; 16: 1175–1188.
54. Grossman SA, Trump DL, Chen DC et al. Cerebrospinal fluid flow abnormalities in patients with neoplastic meningitis. An evaluation using 111indium-DTPA ventriculography. *Am J Med* 1982; 73: 641–647.
55. Glantz MJ, Hall WA, Cole BF et al. Diagnosis, management, and survival of patients with leptomeningeal cancer based on cerebrospinal fluid-flow status. *Cancer* 1995; 75: 2919–2931.
56. Glantz MJ, Cole BF, Glantz LK et al. Cerebrospinal fluid cytology in patients with cancer: minimizing false-negative results. *Cancer* 1998; 82: 733–739.
57. Rogers LR, Duchesneau PM, Nunez C et al. Comparison of cisternal and lumbar CSF examination in leptomeningeal metastasis. *Neurology* 1992; 42: 1239–1241.
58. Dux R, Kindler-Röhrborn A, Annas M et al. A standardized protocol for flow cytometric analysis of cells isolated from cerebrospinal fluid. *J Neurol Sci* 1994; 121: 74–78.
59. Pan Z, Yang G, Wang Y et al. Thinprep plus Papanicolaou stain method is more sensitive than cytospin-coupled Wright Giemsa stain method in cerebrospinal fluid cytology for diagnosis of leptomeningeal metastasis from solid tumors. *PLoS One* 2015; 10: e0122016.
60. Quijano S, López A, Manuel Sancho J et al. Identification of leptomeningeal disease in aggressive B-cell non-Hodgkin's lymphoma: improved sensitivity of flow cytometry. *J Clin Oncol* 2009; 27: 1462–1469.
61. Patel AS, Allen JE, Dicker DT et al. Identification and enumeration of circulating tumor cells in the cerebrospinal fluid of breast cancer patients with central nervous system metastases. *Oncotarget* 2011; 2: 752–760.
62. Le Rhun E, Massin F, Tu Q et al. Development of a new method for identification and quantification in cerebrospinal fluid of malignant cells from breast carcinoma leptomeningeal metastasis. *BMC Clin Pathol* 2012; 12: 21.

63. Lee JS, Melisko ME, Magbanua MJ et al. Detection of cerebrospinal fluid tumor cells and its clinical relevance in leptomeningeal metastasis of breast cancer. *Breast Cancer Res Treat* 2015; 154: 339–349.
64. Milojkovic Kerlaan B, Pluim D, Bol M et al. EpCAM-based flow cytometry in cerebrospinal fluid greatly improves diagnostic accuracy of leptomeningeal metastases from epithelial tumors. *Neuro Oncol* 2016; 18: 855–862.
65. Ma C, Lv Y, Jiang R et al. Novel method for the detection and quantification of malignant cells in the CSF of patients with leptomeningeal metastasis of lung cancer. *Oncol Lett* 2016; 11: 619–623.
66. Subirá D, Simó M, Illán J et al. Diagnostic and prognostic significance of flow cytometry immunophenotyping in patients with leptomeningeal carcinomatosis. *Clin Exp Metastasis* 2015; 32: 383–391.
67. Tu Q, Wu X, Le Rhun E et al. CellSearch technology applied to the detection and quantification of tumor cells in CSF of patients with lung cancer leptomeningeal metastasis. *Lung Cancer* 2015; 90: 352–357.
68. Magbanua MJ, Roy R, Sosa EV et al. Genome-wide copy number analysis of cerebrospinal fluid tumor cells and their corresponding archival primary tumors. *Genomics Data* 2014; 2: 60–62.
69. Li Y, Pan W, Connolly ID et al. Tumor DNA in cerebral spinal fluid reflects clinical course in a patient with melanoma leptomeningeal brain metastases. *J Neurooncol* 2016; 128: 93–100.
70. Sasaki S, Yoshioka Y, Ko R et al. Diagnostic significance of cerebrospinal fluid EGFR mutation analysis for leptomeningeal metastasis in non-small-cell lung cancer patients harboring an active EGFR mutation following gefitinib therapy failure. *Respir Investig* 2016; 54: 14–19.
71. Shingyoji M, Kageyama H, Sakaida T et al. Detection of epithelial growth factor receptor mutations in cerebrospinal fluid from patients with lung adenocarcinoma suspected of neoplastic meningitis. *J Thorac Oncol* 2011; 6: 1215–1220.
72. Yang H, Cai L, Zhang Y et al. Sensitive detection of EGFR mutations in cerebrospinal fluid from lung adenocarcinoma patients with brain metastases. *J Mol Diagn* 2014; 16(5): 558–563.
73. Le Rhun E, Rudá R, Devos P et al. Diagnosis and treatment patterns for patients with leptomeningeal metastasis from solid tumors across Europe. *J Neuro-Oncol* 2017 [Epub ahead of print].
74. Pardridge WM. CSF, blood-brain barrier, and brain drug delivery. *Expert Opin Drug Deliv* 2016; 13: 963–975.
75. Boogerd W, van den Bent MJ, Koehler PJ et al. The relevance of intraventricular chemotherapy for leptomeningeal metastasis in breast cancer: a randomised study. *Eur J Cancer* 2004; 40: 2726–2733.
76. Glantz MJ, Cole BF, Recht L et al. High-dose intravenous methotrexate for patients with nonleukemic leptomeningeal cancer: is intrathecal chemotherapy necessary? *J Clin Oncol* 1998; 16: 1561–1567.
77. Bokstein F, Lossos A, Siegal T. Leptomeningeal metastases from solid tumors: a comparison of two prospective series treated with and without intra-cerebrospinal fluid chemotherapy. *Cancer* 1998; 82: 1756–1763.
78. Soffietti R, Abacioglu U, Baumert B et al. Diagnosis and treatment of brain metastases from solid tumors: guidelines from the European Association of Neuro-Oncology (EANO). *Neuro Oncol* 2017; 19: 162–174.
79. Church DN, Modgil R, Guglani S et al. Extended survival in women with brain metastases from HER2 overexpressing breast cancer. *Am J Clin Oncol* 2008; 31: 250–254.
80. Brufsky AM, Mayer M, Rugo HS et al. Central nervous system metastases in patients with HER2-positive metastatic breast cancer: incidence, treatment, and survival in patients from registHER. *Clin Cancer Res* 2011; 17: 4834–4843.
81. Lin NU, Carey LA, Liu MC et al. Phase II trial of lapatinib for brain metastases in patients with human epidermal growth factor receptor 2-positive breast cancer. *J Clin Oncol* 2008; 26: 1993–1999.
82. Lin NU, Diéras V, Paul D et al. Multicenter phase II study of lapatinib in patients with brain metastases from HER2-positive breast cancer. *Clin Cancer Res* 2009; 15: 1452–1459.
83. Toi M, Iwata H, Fujiwara Y et al. Lapatinib monotherapy in patients with relapsed, advanced, or metastatic breast cancer: efficacy, safety, and biomarker results from Japanese patients phase II studies. *Br J Cancer* 2009; 101: 1676–1682.
84. Bachelot T, Romieu G, Campone M et al. Lapatinib plus capecitabine in patients with previously untreated brain metastases from HER2-positive metastatic breast cancer (LANDSCAPE): a single-group phase 2 study. *Lancet Oncol* 2013; 14: 64–71.
85. Metro G, Foglietta J, Russillo M et al. Clinical outcome of patients with brain metastases from HER2-positive breast cancer treated with lapatinib and capecitabine. *Ann Oncol* 2011; 22: 625–630.
86. Sutherland S, Ashley S, Miles D et al. Treatment of HER2-positive metastatic breast cancer with lapatinib and capecitabine in the lapatinib expanded access programme, including efficacy in brain metastases—the UK experience. *Br J Cancer* 2010; 102: 995–1002.
87. Bartsch R, Berghoff AS, Vogl U et al. Activity of T-DM1 in Her2-positive breast cancer brain metastases. *Clin Exp Metastasis* 2015; 32: 729–737.
88. Keith KC, Lee Y, Ewend MG et al. Activity of trastuzumab-emtansine (TDM1) in HER2-positive breast cancer brain metastases: a case series. *Cancer Treat Commun* 2016; 7: 43–46.
89. Jacot W, Pons E, Frenel JS et al. Efficacy and safety of trastuzumab emtansine (T-DM1) in patients with HER2-positive breast cancer with brain metastases. *Breast Cancer Res Treat* 2016; 157: 307–318.
90. Dudani S, Mazzarello S, Hilton J et al. Optimal management of leptomeningeal carcinomatosis in breast cancer patients—a systematic review. *Clin Breast Cancer* 2016; 16: 456–470.
91. Park IH, Kwon Y, Ro JY et al. Concordant HER2 status between metastatic breast cancer cells in CSF and primary breast cancer tissue. *Breast Cancer Res Treat* 2010; 123: 125–128.
92. Wu PF, Lin CH, Kuo CH et al. A pilot study of bevacizumab combined with etoposide and cisplatin in breast cancer patients with leptomeningeal carcinomatosis. *BMC Cancer* 2015; 15: 299.
93. Li M, Zhang Q, Fu P et al. Pemetrexed plus platinum as the first-line treatment option for advanced non-small cell lung cancer: a meta-analysis of randomized controlled trials. *PLoS One* 2012; 7: e37229.
94. Zimmermann S, Dziadziszko R, Peters S. Indications and limitations of chemotherapy and targeted agents in non-small cell lung cancer brain metastases. *Cancer Treat Rev* 2014; 40: 716–722.
95. Besse B, Le Moulec S, Mazières J et al. Bevacizumab in patients with nonsquamous non-small cell lung cancer and asymptomatic, untreated brain metastases (BRAIN): a nonrandomized, phase II study. *Clin Cancer Res* 2015; 21: 1896–1903.
96. Barlesi F, Mazieres J, Merlio JP et al. Routine molecular profiling of patients with advanced non-small-cell lung cancer: results of a 1-year nationwide programme of the French Cooperative Thoracic Intergroup (IFCT). *Lancet* 2016; 387: 1415–1426.
97. Umemura S, Tsubouchi K, Yoshioka H et al. Clinical outcome in patients with leptomeningeal metastasis from non-small cell lung cancer: Okayama Lung Cancer Study Group. *Lung Cancer* 2012; 77: 134–139.
98. Kawamura T, Hata A, Takeshita J et al. High-dose erlotinib for refractory leptomeningeal metastases after failure of standard-dose EGFR-TKIs. *Cancer Chemother Pharmacol* 2015; 75: 1261–1266.
99. Jackman DM, Cioffredi LA, Jacobs L et al. A phase I trial of high dose gefitinib for patients with leptomeningeal metastases from non-small cell lung cancer. *Oncotarget* 2015; 6: 4527–4536.
100. Tetsumoto S, Osa A, Kijima T et al. Two cases of leptomeningeal metastases from lung adenocarcinoma which progressed during gefitinib therapy but responded to erlotinib. *Int J Clin Oncol* 2012; 17: 155–159.
101. Hoffknecht P, Tufman A, Wehler T et al. Efficacy of the irreversible ErbB family blocker afatinib in epidermal growth factor receptor (EGFR) tyrosine kinase inhibitor (TKI)-pretreated non-small-cell lung cancer patients with brain metastases or leptomeningeal disease. *J Thorac Oncol* 2015; 10: 156–163.
102. Mok TS, Wu Y-L, Ahn M-J et al. Osimertinib or platinum-pemetrexed in EGFR T790M-positive lung cancer. *N Engl J Med* 2017; 376: 629–640.
103. Togashi Y, Masago K, Masuda S et al. Cerebrospinal fluid concentration of gefitinib and erlotinib in patients with non-small cell lung cancer. *Cancer Chemother Pharmacol* 2012; 70: 399–405.
104. Yang JCH, Kim DW, Kim SW et al. Osimertinib activity in patients (pts) with leptomeningeal (LM) disease from non-small cell lung cancer (NSCLC): Updated results from BLOOM, a phase I study. *J Clin. Oncol* 2016; 34, suppl: 9002.

105. Solomon BJ, Cappuzzo F, Felip E et al. Intracranial efficacy of crizotinib versus chemotherapy in patients with advanced ALK-positive non-small-cell lung cancer: results from PROFILE 1014. *J Clin Oncol* 2016; 34: 2858–2865.
106. Zhang I, Zaorsky NG, Palmer JD et al. Targeting brain metastases in ALK-rearranged non-small-cell lung cancer. *Lancet Oncol* 2015; 16: e510–e521.
107. Brahmer J, Reckamp KL, Baas P et al. Nivolumab versus docetaxel in advanced squamous-cell non-small-cell lung cancer. *N Engl J Med* 2015; 373: 123–135.
108. Borghaei H, Paz-Ares L, Horn L et al. Nivolumab versus docetaxel in advanced nonsquamous non-small-cell lung cancer. *N Engl J Med* 2015; 373: 1627–1639.
109. Herbst RS, Baas P, Kim DW et al. Pembrolizumab versus docetaxel for previously treated, PD-L1-positive, advanced non-small-cell lung cancer (KEYNOTE-010): a randomised controlled trial. *Lancet* 2016; 387: 1540–1550.
110. Rittmeyer A, Barlesi F, Rittmeyer A, Barlesi F, Waterkamp D et al. Atezolizumab versus docetaxel in patients with previously treated non-small-cell lung cancer (OAK): a phase 3, open-label, multicentre randomised controlled trial. *Lancet* 2017; 389: 255–265.
111. Goldberg SB, Gettinger SN, Mahajan A et al. Pembrolizumab for patients with melanoma or non-small-cell lung cancer and untreated brain metastases: early analysis of a non-randomised, open-label, phase 2 trial. *Lancet Oncol* 2016; 17: 976–983.
112. Margolin K, Ernstoff MS, Hamid O et al. Ipilimumab in patients with melanoma and brain metastases: an open-label, phase 2 trial. *Lancet Oncol* 2012; 13: 459–465.
113. Konstantinou MP, Dutriaux C, Gaudy-Marqueste C et al. Ipilimumab in melanoma patients with brain metastasis: a retrospective multicentre evaluation of thirty-eight patients. *Acta Derm Venereol* 2014; 94: 45–49.
114. Gibney GT, Forsyth PA, Sondak VK. Melanoma in the brain: biology and therapeutic options. *Melanoma Res* 2012; 22: 177–183.
115. Dummer R, Goldinger SM, Turtzchi CP et al. Vemurafenib in patients with BRAF(V600) mutation-positive melanoma with symptomatic brain metastases: final results of an open-label pilot study. *Eur J Cancer* 2014; 50: 611–621.
116. Fennira F, Pagès C, Schneider P et al. Vemurafenib in the French temporary authorization for use metastatic melanoma cohort: a single-centre trial. *Melanoma Res* 2014; 24: 75–82.
117. Long GV, Trefzer U, Davies MA et al. Dabrafenib in patients with Val600Glu or Val600Lys BRAF-mutant melanoma metastatic to the brain (BREAK-MB): a multicentre, open-label, phase 2 trial. *Lancet Oncol* 2012; 13: 1087–1095.
118. Siegal T. Leptomeningeal metastases: rationale for systemic chemotherapy or what is the role of intra-CSF-chemotherapy? *J Neurooncol* 1998; 38: 151–157.
119. Lassman AB, Abrey LE, Shah GD et al. Systemic high-dose intravenous methotrexate for central nervous system metastases. *J Neurooncol* 2006; 78: 255–260.
120. Chahal J, Stopeck A, Clarke K et al. Intravenous thiotepa for treatment of breast cancer-related leptomeningeal carcinomatosis: case series. *Neurol Sci* 2015; 36: 1691–1693.
121. Benjamin JC, Moss T, Moseley RP et al. Cerebral distribution of immunconjugate after treatment for neoplastic meningitis using an intrathecal radiolabeled monoclonal antibody. *Neurosurgery* 1989; 25: 253–258.
122. Burch PA, Grossman SA, Reinhard CS. Spinal cord penetration of intrathecally administered cytarabine and methotrexate: a quantitative autoradiographic study. *J Natl Cancer Inst* 1988; 80: 1211–1216.
123. Blaney SM, Cole DE, Godwin K et al. Intrathecal administration of topotecan in nonhuman primates. *Cancer Chemother Pharmacol* 1995; 36: 121–124.
124. Glantz MJ, Van Horn A, Fisher R, Chamberlain MC. Route of intracerebrospinal fluid chemotherapy administration and efficacy of therapy in neoplastic meningitis. *Cancer* 2010; 116: 1947–1952.
125. Shapiro WR, Schmid M, Glantz M, Miller JJ. A randomized phase III/IV study to determine benefit and safety of cytarabine liposome injection for treatment of neoplastic meningitis. *J Clin Oncol* 2006; 24 (18 Suppl): 1528.
126. Zairi F, Le Rhun E, Bertrand N et al. Complications related to the use of an intraventricular access device for the treatment of leptomeningeal metastases from solid tumor: a single centre experience in 112 patients. *J Neurooncol* 2015; 124: 317–323.
127. Kennedy BC, Brown LT, Komotar RJ, McKhann GM 2nd. Stereotactic catheter placement for Ommaya reservoirs. *J Clin Neurosci* 2016; 27: 44–47.
128. Morgenstern PF, Connors S, Reiner AS, Greenfield JP. Image guidance for placement of Ommaya reservoirs: comparison of fluoroscopy and frameless stereotactic navigation in 145 patients. *World Neurosurg* 2016; 93: 154–158.
129. Gwak HS, Joo J, Shin SH et al. Ventriculolumbar perfusion chemotherapy with methotrexate for treating leptomeningeal carcinomatosis: a Phase II Study. *Oncologist* 2014; 19: 1044–1045.
130. Grossman SA, Finkelstein DM, Ruckdeschel JC et al. Randomized prospective comparison of intraventricular methotrexate and thiotepa in patients with previously untreated neoplastic meningitis. Eastern Cooperative Oncology Group. *J Clin Oncol* 1993; 11: 561–569.
131. Glantz MJ, Jaeckle KA, Chamberlain MC et al. A randomized controlled trial comparing intrathecal sustained-release cytarabine (DepoCyt) to intrathecal methotrexate in patients with neoplastic meningitis from solid tumors. *Clin Cancer Res* 1999; 5: 3394–3402.
132. Hitchins RN, Bell DR, Woods RL, Levi JA. A prospective randomized trial of single-agent versus combination chemotherapy in meningeal carcinomatosis. *J Clin Oncol* 1987; 5: 1655–1662.
133. Cole BF, Glantz MJ, Jaeckle KA et al. Quality-of-life-adjusted survival comparison of sustained-release cytosine arabinoside versus intrathecal methotrexate for treatment of solid tumor neoplastic meningitis. *Cancer* 2003; 97: 3053–3060.
134. Zagouri F, Sergentanis TN, Bartsch R et al. Intrathecal administration of trastuzumab for the treatment of meningeal carcinomatosis in HER2-positive metastatic breast cancer: a systematic review and pooled analysis. *Breast Cancer Res Treat* 2013; 139: 13–22.
135. Chamberlain MC, Kormanik PA. Prognostic significance of 111indium-DTPA CSF flow studies in leptomeningeal metastases. *Neurology* 1996; 46: 1674–1677.
136. Chamberlain MC. Radioisotope CSF flow studies in leptomeningeal metastases. *J Neurooncol* 1998; 38: 135–140.
137. Pan Z, Yang G, He H et al. Concurrent radiotherapy and intrathecal methotrexate for treating leptomeningeal metastasis from solid tumors with adverse prognostic factors: a prospective and single-arm study. *Int J Cancer* 2016; 139: 1864–1872.
138. Chamberlain MC, Johnston SK. Neoplastic meningitis: survival as a function of cerebrospinal fluid cytology. *Cancer* 2009; 115: 1941–1946.
139. Weller M, Stupp R, Wick W. Epilepsy meets cancer: when, why, and what to do about it? *Lancet Oncol* 2012; 13: e375–e382.
140. Tremont-Lukats IW, Ratilal BO, Armstrong T, Gilbert MR. Antiepileptic drugs for preventing seizures in people with brain tumors. *Cochrane Database Syst Rev* 2008; CD004424.
141. Jung TY, Chung WK, Oh JJ. The prognostic significance of surgically treated hydrocephalus in leptomeningeal metastases. *Clin Neurol Neurosurg* 2014; 119: 80–83.
142. Nigim F, Critchlow JF, Kasper EM. Role of ventriculoperitoneal shunting in patients with neoplasms of the central nervous system: an analysis of 59 cases. *Mol Clin Oncol* 2015; 3: 1381–1386.
143. Zhang XH, Wang XG, Piao YZ et al. Lumboperitoneal shunt for the treatment of leptomeningeal metastasis. *Med Hypotheses* 2015; 84: 506–508.
144. Yamashiro S, Hitoshi Y, Tajiri S et al. Palliative lumboperitoneal shunt for leptomeningeal metastasis-related hydrocephalus: a case series. *Palliat Med* 2017; 31: 93–96.
145. Pace A, Linda Dirven L, Koekkoek JAF et al., on behalf of the European Association of Neuro-Oncology palliative care task force. EANO guidelines for palliative care in adult glioma patients. *Lancet Oncol* 2017; 18: e330–e340.
146. Brainin M, Barnes M, Baron JC et al. Guidance for the preparation of neurological management guidelines by EFNS scientific task forces—revised recommendations 2004. *Eur J Neurol* 2004; 11: 577–581.
147. Dykewicz CA. Summary of the guidelines for preventing opportunistic infections among hematopoietic stem cell transplant recipients. *Clin Infect Dis* 2001; 33: 139–144.